

## REATTACHMENT OF FRACTURED CROWN FRAGMENT: A CONSERVATIVE APPROACH

NAVDHA CHAUDHARY<sup>a</sup>, BABITA AHLAWAT<sup>1b</sup>, ASHOK KUMAR<sup>c</sup>, VIJAYLAXMY<sup>d</sup> AND VINOD BHARDWAJ<sup>e</sup>

<sup>a</sup>Department of Pedodontics and Preventive Dentistry, Eklavya Dental College, Kotputli, Jaipur, Rajasthan, India

<sup>1b</sup>Department of Dentistry, SHKM GMC, Nalhar, Mewat, Haryana, India

<sup>c</sup>Department of ENT, SHKM GMC, Nalhar, Mewat, Haryana, India

<sup>e</sup>Department of Pharmacology, SHKM GMC, Nalhar, Mewat, Haryana, India

### ABSTRACT

Anterior tooth trauma occurs frequently in children and adolescents. Crown fractures account for the majority of dental trauma in the permanent dentition (26-76% of dental injuries). The most common etiologic factors responsible are automobile accidents, falls and sports injuries. They can cause esthetic, phonetic and functional problems and also lead to anxiety as well as psychological stress in the traumatized patient. There are many ways to treat different types of traumas. When a fragment is recovered, the most conservative treatment option for a crown fracture is the bonding of the fragment to the fractured tooth. Progressive development of adhesive dentistry has enabled clinicians to re-attach the original fragment to the tooth mechanically and chemically. Several advantages in this treatment are responsible for its widespread use. This technique produces good, lasting esthetic results, as it maintains the original anatomic shape, color, and texture of the tooth. This article presents a case report of esthetic reattachment of a fractured fragment of permanent central incisor using contemporary composites by direct adhesives techniques.

**KEYWORDS :** Anterior tooth trauma, Fragment reattachment, Adhesive resin, Calcium hydroxide pulpotomy

Anterior tooth trauma is a common form of injury that mainly affects children and adolescents. It has been estimated that about one quarter of the population under the age of 18 sustain traumatic injury in the form of anterior crown fracture. (Murchison et al, 1999, Petti and Tarsitani, 1996) Ninety-six percent of these traumatic injuries involve maxillary incisors (80% central incisors and 16% lateral incisors). (Andreasen and Ravn, 1972)

In the dental literature, numerous treatment modalities have been introduced for the reconstruction of fractured teeth such as resin or ceramic crowns and resin composite restorations with or without posts. However, the progressive development of adhesive dentistry technology enables clinicians to re-attach the original fragment to the tooth mechanically and chemically. Re-attachment of a tooth fragment should be preferable to restoring fractured teeth when the fragment is available. Several advantages in this treatment are responsible for its widespread use.

- 1) It is a conservative procedure; it maintains the original tooth contours and translucence as the patient's own incisal enamel.
- 2) Appears more natural than any other composite.
- 3) The color match of the remaining crown portion and its color stability over time and incisal edge will wear in

harmony with the adjacent teeth, as a composite restoration tends to wear faster than enamel. (Busato et al, 1998).

- 4) Total chairside time for re-attachment of incisal edge is less than constructing a composite resin incisal edge (Cavalleri and Zerman, 1995).
- 5) The method is much more economical.

However, sometimes, the remaining tooth substrate is discolored owing to breakdown of the pulpal blood vessels and there may be a color transition between the tooth and the reattached fragment.

A patient with a fractured anterior tooth is usually emotionally upset about his or her appearance, and also suffers some discomfort like sensitivity to cold stimuli. Quick restoration of the esthetic appearance and relief of discomfort for these patients within a single appointment by preserving the natural tooth structure may lead to a positive emotional and social response from the patient.

The following re-attachment strategies have been advocated for re-attaching a detached tooth fragment to the remaining tooth:

1. Placement of a circumferential bevel before re-attaching the fragment (Simonsen, 1979 and Burke, 1991 and Walker, 1996).

<sup>1</sup>Corresponding author

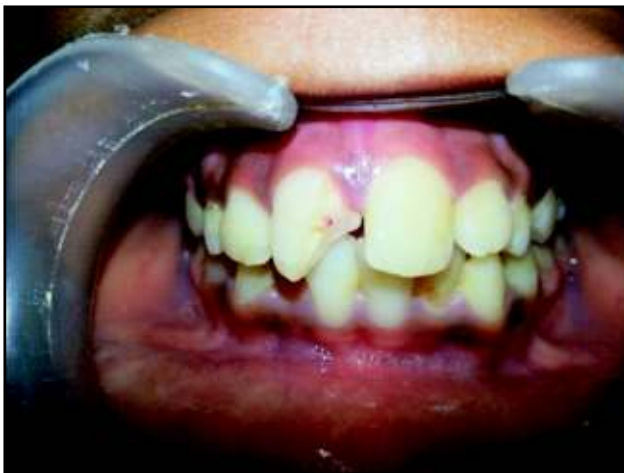2. Placement of an external chamfer at the fracture line after bonding (Baratieri, 1994).
3. Use of a v-shaped enamel notch.
4. Placement of an internal groove (Walker, 1996 and Baratieri, 1994).
5. Leaving a superficial overcontour of restorative material over the fracture line (Reis et al, 2001 and Badami et al, 1995).

**Case Report 1**

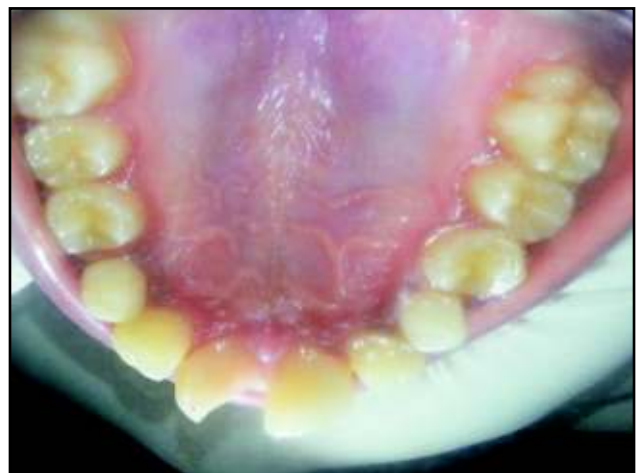A 11 year old girl reported to the Department of Paedodontics and Preventive dentistry, B.R.S Dental college following fracture of the crown in right maxillary

central incisor. (Fig 1.1, 1.2) The trauma had occurred due to a fall during sports activity about 6-7 days ago. The broken tooth fragment was recovered intact by the patient herself at the accident site. (Fig 1.3) Patient cleaned it in tap water and wrapped in cotton and brought it to the hospital. Patient's medical history was non contributory. Clinical examination revealed a complicated crown fracture involving enamel, dentine and pulp (Ellis class III). There was no mobility of the injured tooth. The surrounding hard and soft tissues did not reveal any form of injury. Electronic pulp testing showed asymmetric response of the two central incisors.

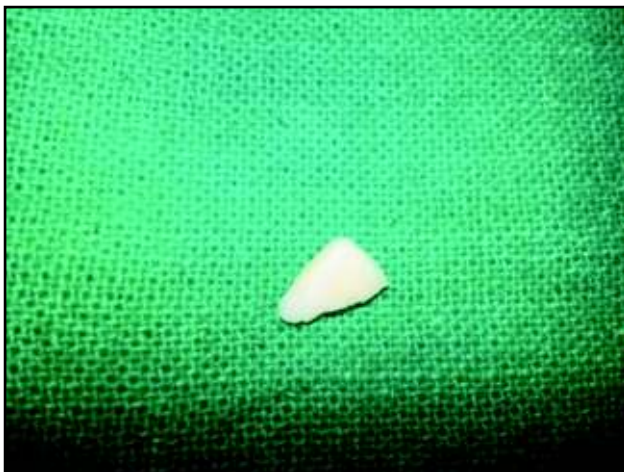**Case - 1**



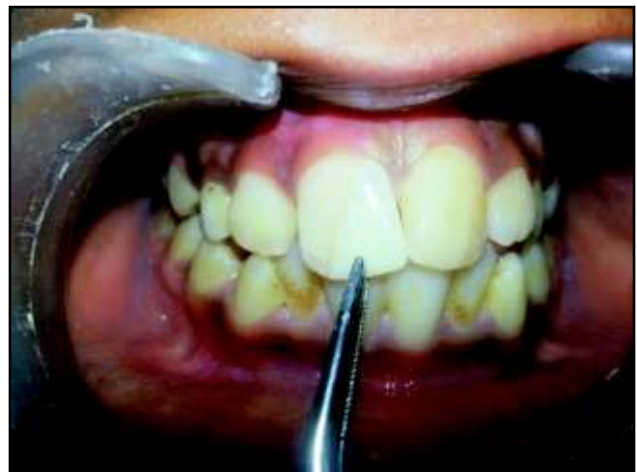**Figure 1.1: Preoperative Photograph Showing ELLIS III # i.r.t 11 Frontal View**



**Figure 1.2: Preoperative Photograph Showing ELLIS III # i.r.t 11 Palatal View**



**Figure 1.3: Photograph Showing Fractured Tooth Fragment of 11**



**Figure 1.4: Fractured Fragment Checked for Approximation i.r.t 11**



Figure 1.5 : Preoperative IOPA i.r.t 11

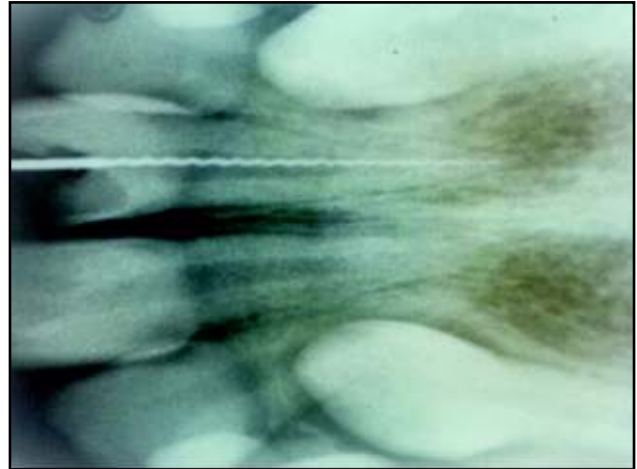


Figure 1.6 : Working Length Determination i.r.t 11

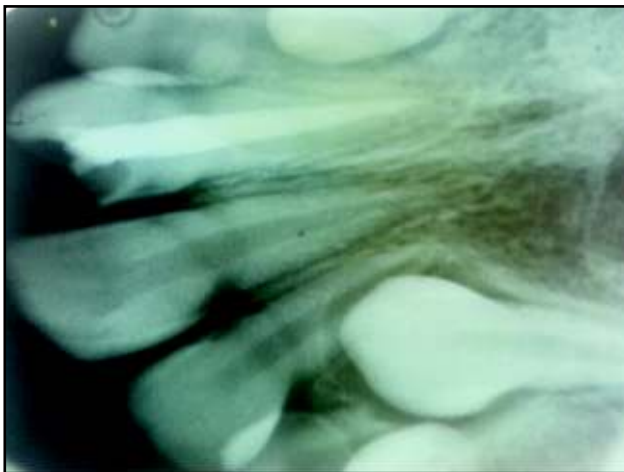


Figure 1.7 : IOPA Showing Obturation i.r.t 11

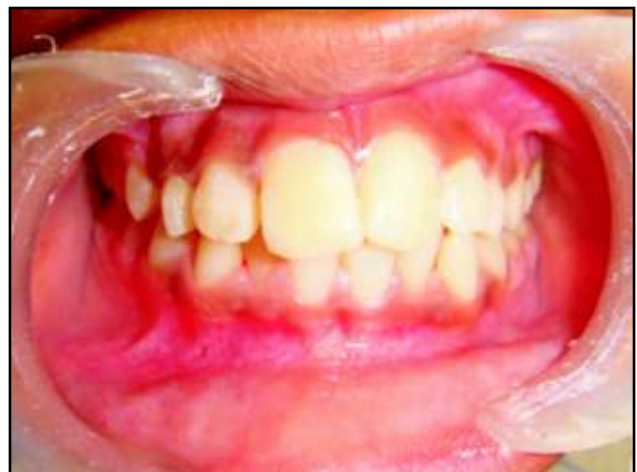

Figure 1.8 : Postoperative Radiograph Showing Reattachment of Fractured Fragment and Esthetic Build of 11

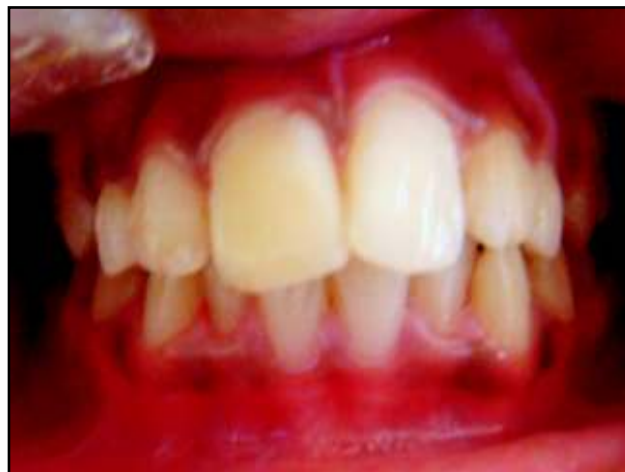

Figure 1.9 : Follow Up After 6 Months

Periapical radiograph showed a complete root development. No periapical pathology or alveolar bone fracture was appreciated radiographically. (Fig 1.5) Child's parents were informed of various treatment options and they preferred to retain the fractured fragment. The tooth fragment was checked for approximation with the remaining crown. (Fig 1.4)The fractured fragment was discolored. After that it was bathed in chlorhexidine solution for 2 minutes for disinfection and then transferred to normal saline till the time of restoration to prevent dehydration.

After administration of local anesthesia and isolation of tooth, retraction cord was placed around the right central incisor. Access opening was done and working length was determined. Biomechanical preparation was done and access cavity was sealed with cavit. After 48 hours obturation was done with gutta-percha and access cavity was restored with GIC. (Fig 1.7)

In order to guide the correct adaptation of tooth fragment a round diamond bur was used to make notches of 1-1.5 mm on approximal sides of enamel of both the fragment and the remaining crown structure. After that a bevel of 45 degree was made on enamel margin of the remaining crown structure.

Both the fragment and the remaining tooth were acid etched using 37% orthophosphoric acid (Meta etchant gel) for 15 seconds. Etchant gel was removed with aspirator

tube and rinsed for 20 seconds. Excess water was removed with a brief jet of air so that the surface was left visibly wet. A double coat of bonding agent (SwissTec, coltene) was applied using a microbrush to both fragment and the tooth and light cured for 20 seconds. A flowable resin (coltene, whaledent) was placed in the notches and fractured surface of the tooth. The fragment was repositioned and then flowable resin was light cured for 30 seconds both labially and palatally each. The excess material at the restorative margins was finished and polished with finishing burs and discs.

The chasm between the fractured fragment and remaining tooth was masked with the help of an opaque resin and after doing shade selection with the help of contralateral tooth, a layer of composite was placed including the incisal shades to complete the restoration. (Fig 1.8)

#### Case Report 2

A 10 year old boy reported to the Department of Paedodontics and Preventive dentistry, B.R.S Dental College following fracture of the crown in left maxillary central incisor. (Fig 2.1, 2.2)The trauma had occurred due to fall from bicycle three days back. The broken tooth fragment was recovered intact by the patient's mother at the accident site and brought to the hospital wrapped in a paper tissue. (Fig 2.3) Patient's medical history was non contributory. Clinical examination revealed a complicated crown fracture

#### Case - 2

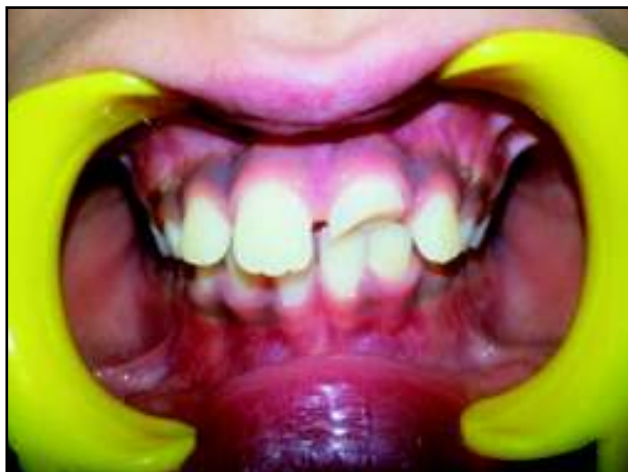

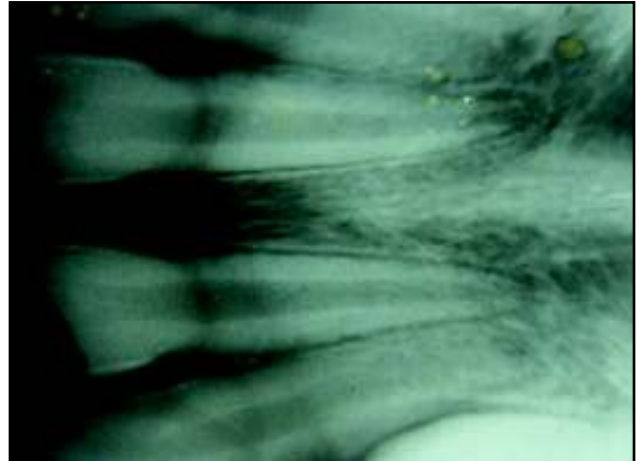
Figure 2.1: Preoperative Photograph Showing ELLIS III # i.r.t 21 Frontal View

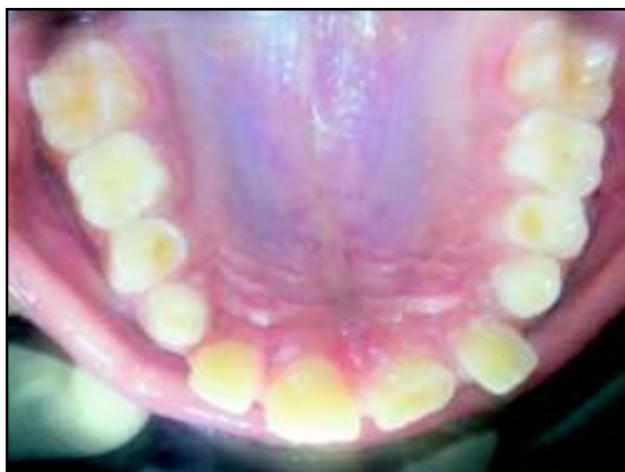
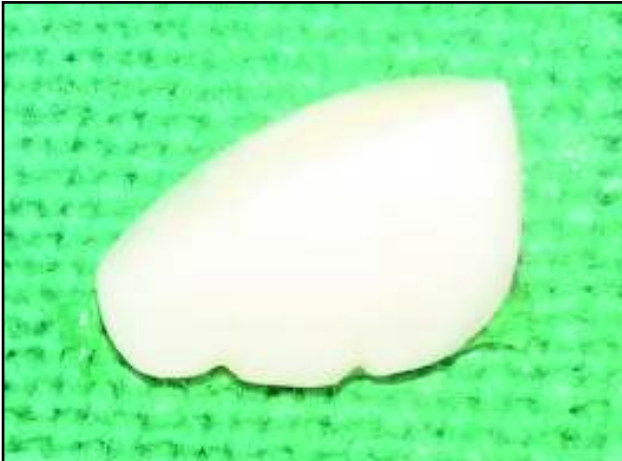
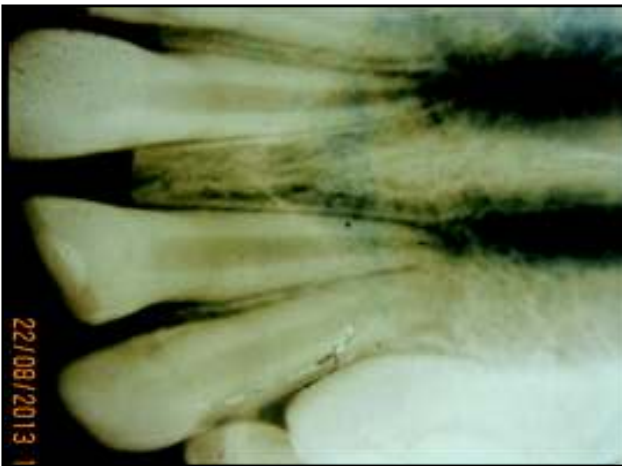Figure 2.2: Preoperative Photograph Showing ELLIS III # i.r.t 21 - Palatal View



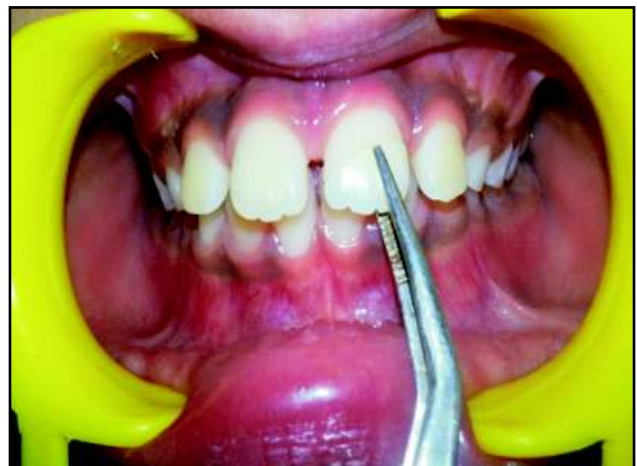**Figure 2. 3: Photograph Showing Fractured Tooth Fragment of 21**



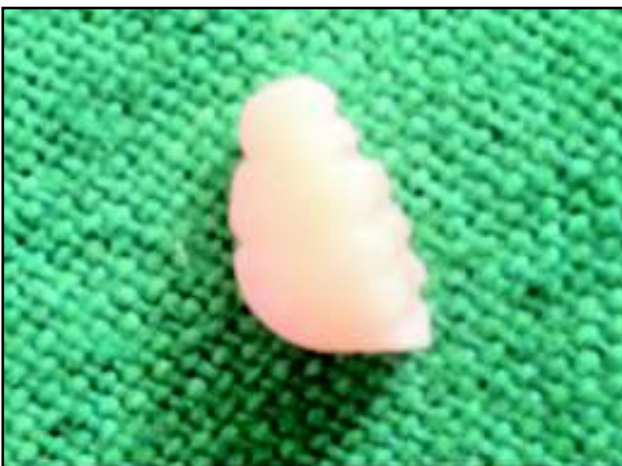**Figure 2.4: Preoperative IOPA Showing ELLIS III i.r.t 21**



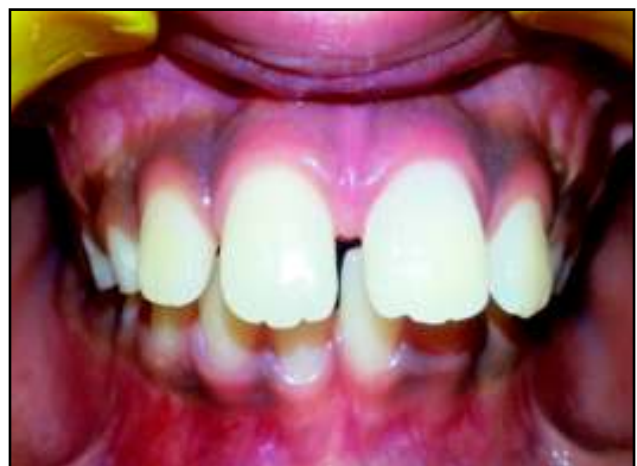**Figure 2.5: IOPA Showing Partial Pulpotomy i.r.t 21**



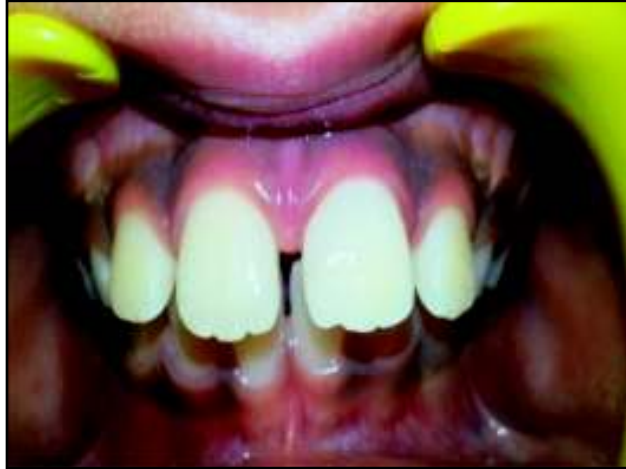**Figure 2.6: Fractured Fragment Checked for Approximation i.r.t 21**



**Figure 2.7: Photograph Showing Notches Made on the Fractured Surface of Tooth Fragment**



**Figure 2.8: Postoperative Photograph Showing Reattachment of Fractured Fragment and Esthetic Build Up of 21**



**Figure 2.9: Follow up After 6 Months**

involving enamel, dentine and pulp (Ellis class 3). There was no mobility of the injured tooth.

The fractured fragment was disinfected with NaOH and rinsed thoroughly with water. Examination of the fragment revealed a very clean break. The pulp chamber may be seen but there was no sign of pulpal exposure or blood. There was no fracture of the root.

Juxtaposition of the fragment with the tooth showed that the margins of each fitted well against each other and no interfragmentary space was present. (Fig 2.6) The pieces fitted together so well that the use of a resin composite would have prevented the best apposition of the tooth fragments and might have added to tooth length. The fractured fragment had lost its original shine and lustre and was discolored.

The injured tooth showed no periapical pathology and did not show symptoms of any painful pulpitis. (Fig 2.4) A partial pulpotomy was planned as a treatment option and explained to the parents.

After administration of local anesthesia and isolation of tooth, the visible opening of the pulp chamber was slightly widened with a round diamond bur to a complete coronal access without damaging the labial and lingual walls of the crown. The coronally inflamed pulp was extirpated with the help of a spoon excavator. The hemorrhage was controlled with help of moistened cotton pellets in saline. After which, a layer of pure calcium hydroxide was placed on the amputation site of the pulp. The cavity was sealed with restorative GIC and patient was

recalled after three weeks to rule out any sensitivity or pain. (Figure 2.5)

On recall appointment, tooth was again checked for vitality and it gave a positive response. To guide the correct adaptation of tooth fragment, no.1 round diamond bur was used to make notches of 1-1.5 mm on approximal sides of enamel of both the fragment and the remaining crown structure. (Fig 2.7) After that a bevel of 45 degree was made on enamel margin of the remaining crown structure.

Both the fragment and the remaining tooth were acid etched using 37% orthophosphoric acid (Meta etchant gel) for 15 seconds. Etchant gel was removed with aspirator tube and rinsed for 20 seconds. Excess water was removed with a brief jet of air so that the surface was left visibly wet. A double coat of bonding agent (SwissTec, coltene) was applied using a microbrush to both fragment and the tooth and light cured for 20 seconds. A flowable resin (coltene, whaledent) was placed in the notches and fractured surface of the tooth. The fragment was repositioned and then flowable resin was light cured for 30 seconds both labially and palatally each. The excess material at the restorative margins was finished and polished with finishing burs and discs.

The chasm between the fractured fragment and remaining tooth was masked with the help of an opaque resin and after doing shade selection with the help of contralateral tooth, a layer of composite was placed including the incisal shades to complete the restoration. (Fig 2.8)

## DISCUSSION

Anterior tooth trauma of maxillary central incisors is the most common form of injury that mainly affects children and adolescents due to their position in the arch.

There are various treatment options available for the restoration of fractured teeth such as direct composite build up and crowns but keeping in mind the patient's age and positive psychological response, reattachment of fractured fragment, if recovered, is relatively a simple and best procedure. With the advancements in the resin composite and bonding systems; chemical and mechanical reattachment of the remaining fragment has become much easier and effective.

Tennery was the first used the acid etch technique for the reattachment of a fractured fragment. Subsequently, similar cases were reported by Starkey and Simonsen.

The fragment reattachment not only gives the patient a psychological satisfaction but also helps in maintaining the original shape, contour and anatomy of the tooth.

The acceptance of this treatment option is always preferred by the patient as well as the parents, but few points should be taken into consideration before reattaching a fractured fragment such as:

- a) Minimal or no violation of the biological width.
- b) Crown fragment should be intact.
- c) Complete approximation of the fragment to the remaining crown structure.

Procedure for reattaching a fragment is similar to a free-hand composite build-up but with the following differences.

- Firstly, the color transition of the sandwiched composite between remaining tooth and reattached fragment should be a seamless.
- Secondly, to improve fracture strength of the repaired complex remaining tooth/composite/fragment), it is advisable to re-hydrate the fragment for at least 30 minutes prior to bonding with the resin composite.

Esthetics, periodontal status and mobility of tooth should be checked periodically by both clinical and radiographic evaluation. Follow up in these patients is of critical importance as the bonded interface between the tooth and the reattached fragment is susceptible to effects of

cyclic fatigue and hydrolytic degradation with time. Further advancements in the resin bonding systems in future can serve to enhance the success of reattachment procedures by increasing the longevity of the restoration.

## CONCLUSION

Reattachment of an intact tooth fragment is a simple, biological and conservative approach of treatment. It serves as a transitional treatment alternative for preteens or teenage patients to postpone definitive treatment until an age where gingival margin contours are relatively stable. Patient as well as parents should be explained the possible outcomes of this treatment option and should be encouraged for regular follow up visits. They should also be informed about the interim nature of this treatment and should be educated about the future prospects of age specific permanent treatment options.

## REFERENCES

- Andreasen F. M., Daugaard-Jensen J., Munksgaard E. C., 1991. Reinforcement of bonded crown fractured incisors with porcelain veneers. *Endod dent traumatol* 7:78-83.
- Andreasen F. M., Noren J. G., Andreasen J. O., Engelhardtson S., Lindh-Stromberg U., 1995. Long-term survival of fragment bonding in the treatment of fractured crowns: a multicenter clinical study. *Quintessence int.*, 26:669-681.
- Andreasen J. O., Ravn J. J., 1972. Epidemiology of traumatic dental injury to primary and permanent teeth in a Danish population sample. *Int J Oral Surg* 1:235-9.
- Busato A. L., Loguercio A. D., Barbosa A. N., Sanseverino Mdo C., Macedo R. P., Baldissere R. A., 1998. Biological restorations using tooth fragments. *Am J Dent.*, 11:46-49.
- Badami A. A., Dunne S. M., Scheer B., 1995. An *in vitro* investigation into the shear bond strengths of two dentine-bonding agents used in the reattachment of incisal edge fragments. *Endod dent traumatol* 11:129-135.
- Burke F. J., 1991. Re-attachment of a fractured central incisor tooth fragment. *Br Dent J.*, 170:223-235.

- Baratieri L. N., Monteiro S. J. R., De Albuquerque F. M., Vieira L. C., De Andrada M. A., De MeloFilho L. C., 1994. Reattachment of a tooth fragment with a “new” adhesive system: a case report. *Quintessence int*, **25**:91-96.
- Baratieri L. N., Monteiro S. J. R., Andrada MAC. Esthetics: direct adhesive restorations on fractured anterior teeth. *Quintessence books, chicago*, 1998.
- Cavalleri G., Zerman N., Traumatic crown fractures in permanent incisors with immature roots: a follow-up study. *Endod Dental Traumatol*, **11**:2946.
- Davis M. J., Roth J. and Levi M., 1983. Marginal integrity of adhesive fracture restorations: chamfer versus bevel. *Quintessence int.*, **14**:1135-1146.
- Murchison D. F., Burke F. J., Worthington R. B., 1999. Incisal edge reattachment: indications for use and clinical technique. *Br Dent J.*, **186**:614-9.
- Petti S., Tarsitani G., 1996. Traumatic injuries to anterior teeth in Italian schoolchildren: prevalence and risk factors. *Endod Dent Traumatol*, **12**:294-7.
- Reis A., Francci C., Loguercio A. D., Carrilho M. R. O., Rodrigues Filho LE. Re-attachment of anterior fractured teeth: fracture strength using different techniques. *Oper dent*, **26**:287-294.
- Simonsen R. J., Traumatic fracture restorations: an alternative use of the acid etch technique. *Quintessenceint*, **10**:15-22.
- Walker M., 1996. Fractured-tooth fragment reattachment. *Gen dent*, **44**:434-436.