

SURGICAL CORRECTION OF DIPHYRSARY HUMERAL FRACTURE IN A PARIAH KITE (*Milvus migrans*)

S. L. GAYATHRI^{a1} AND K. S. SUNIL^b

^aM. V. Sc. Scholar, College of Veterinary Sciences and Animal Husbandry, Bhubaneswar, Orissa University of Agriculture and Technology, Odisha, India

^bSenior Veterinary Surgeon, District Veterinary Centre, Thiruvananthapuram, India

ABSTRACT

A Pariah Kite was presented to the District Veterinary Centre, Thiruvananthapuram with the complaint of inability to fly. Examination of the wing revealed fracture of the humerus. On further investigation with the help of radiograph transverse diphyrsary humeral fracture could be diagnosed. The bird was stabilized with a course of antibiotics, supportives and fluids for three days. The methodology adopted was surgical correction of the fracture using intra medullary pinning technique with help of Steinmann pin. The anaesthetic Protocol included Ketamine @ 44mg/kg BW s/c and Inj. Ketamine 0.3ml s/c. Prior to the surgery the area was aseptically sterilized and an antibiotic umbrella was given. An incision was made on the site of the fracture and bone was exposed. A Steinmann pin of 3mm diameter was introduced through the fractured site to the distal part initially and then to the proximal part with the help of a chuck. The remaining part of the pin protruding out from the bone was cut using a pin cutter. The muscle layer was sutured using PGA 2-0, continuous suture pattern and the skin sutured using interrupted suture pattern using hylon. A padding of Staphban ointment was applied and bandaged the area. Post operatively the bird was given inj. Ceftiofur sodium (Xyrofur® 0.5g) @ 0.91mg/kg BW s/c and inj. Tribivet 0.2ml s/c for 7 days and advised Staphbhan ointment (Povidone iodine) bandaging on alternate days. Advised cage rest and the bird recovered successfully within a months' time.

KEYWORDS: Steinmann Pin, Diphyrsary Fracture, Humerus, Pariah Kite

The techniques used in avian orthopaedics vary in many significant methods from mammalian procedures. Overall, the bones of avians have thinner, more brittle cortices and that the pneumatized are connected to air sacs. Hence, many avian fractures tend to be comminuted and open fractures of pneumatized bones, such as the humerus and femur, can lead to subcutaneous emphysema and respiratory infections. Healing time for avian orthopedic injuries are short when compared to mammals, with clinical firmness often accomplished 3 to 4 weeks postoperatively and full bone healing by 6 weeks after surgery. But, wild avian patients require full return to function for release and any problem that results in a decreased range of motion in any joint may be problematic. Therefore, surgical and coaptation techniques must not compromise joint mobility. Also, fixation devices must be removed after bone healing has occurred because any extra weight on an extremity can compromise survival of the wild bird after release. The avian shoulder joint is comprised of four different bones that function together to provide the power needed for lift and sustained flight. The clavicle and larger coracoid bones serve as struts to support the body during the downbeat of the wings and also to provide attachment for the pectoral muscles which power flight. The scapula is palpable as a ridge over the dorsal aspect of the thoracic wall on either side of the spine. The humerus is a pneumatized bone that articulates

with the radius and larger ulna at the elbow joint, which normally extends to 180 degrees (Redig, 2008). These bones articulate distally at the carpal joint, which normally hyperextends beyond 180 degrees. Distal to the carpus, two carpometacarpal bones articulate with the major and minor digits of the wing. Fractures of the avian humerus tend to be open due to the strong pull of attached flexor muscles. The radial nerve runs caudal to cranial in the mid-diaphysis and must be evaluated and preserved during surgical procedures. Proximal humeral fractures are most often transverse and, because it can be difficult to stabilize these fractures with an intramedullary (IM) pin, the preferred method of fixation is with tension band placement. Fractures of the humeral diaphysis are best repaired with an intramedullary pin tied into an external skeletal fixator (TIF). In open humeral fractures, the IM pin is retrograded into the bone through a dorsal approach. The pin is usually normograded for closed fractures with the entry site for the pin through the dorsal aspect of the distal humerus just proximal to the lateral condyle (Westfall and Egger, 1979). The triceps tendon must be retracted prior to pin insertion at this site. Regardless of the point of insertion, once the fracture has been reduced, the pin is bent at 90 degrees where it exits the bone. Two or more positive threaded cross pins are placed in the proximal and distal fragments of the bone. The cross pins are then linked to the IM pin with a

lightweight bar, which can be metal (Fessa tubular fixator system) or acrylic. Distal humeral fractures are more problematic because there is usually accompanying joint damage, the fractures are often open and there is not good purchase for fixation devices distally. Fixation of a fracture is usually not an emergency. Due to the traumatic nature of most of these injuries, first priority must be given to stabilizing the patient. Emergency treatment of shock, haemorrhage and sepsis must be given first. It is important to assess the patient holistically, including diet, husbandry and concurrent medical conditions, without focusing solely on the obvious injuries. The present study consists of surgical correction of diphysary fracture of humerus in Pariah Kite (*Milvus migrans*), coming under diurnal raptors. The wings are angled and tail is distinctively forked, also are vociferous with a shrill whinnying call.

MATERIALS AND METHODS

A Pariah Kite was presented to the DVC, Thiruvananthapuram with complaint of inability to fly. The wild bird was found grounded by a nature loving youth. Examination of the wing revealed fracture of the humerus. On further investigation with the help of radiograph (Figure 1) transverse diphysary humeral fracture could be diagnosed.

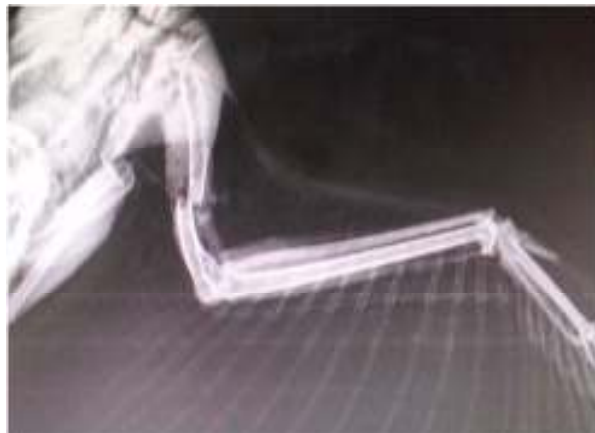


Figure 1: Radiograph showing the transverse diphysary humeral fracture

The bird was stabilized with a course of antibiotics (inj. Xyrofur 2mg s/c) supportives (inj. Tribivet 0.2 ml s/c) and fluids for three days.

Methodology

Surgical correction of the fracture using intra medullary pinning technique with help of Steinmann pin.

Anaesthetic Protocol

Ketamine @ 44mg/kg BW s/c was used, Inj. Ketamine 0.3ml s/c

As a part of the pre – operative measure, the area of fracture was clipped, scrubbed and bandaged the rest of the wings. Prior to the surgery the area was aseptically sterilized and an antibiotic umbrella was given. An incision was made on the site of the fracture using BP blade and handle. The fractured bone was exposed. A Steinmann pin 3mm diameter was introduced through the fractured site to the distal part initially and then to the proximal part with the help of a chuck. The remaining part of the pin protruding out from the bone was cut using a pin cutter. The muscle layer was sutured using PGA 2-0, continuous suture pattern and the skin sutured using interrupted suture pattern using hylon. A padding of Staphban ointment was applied and bandaged the area. Radiograph after the surgical correction showed correct alignment. (Figure 2)

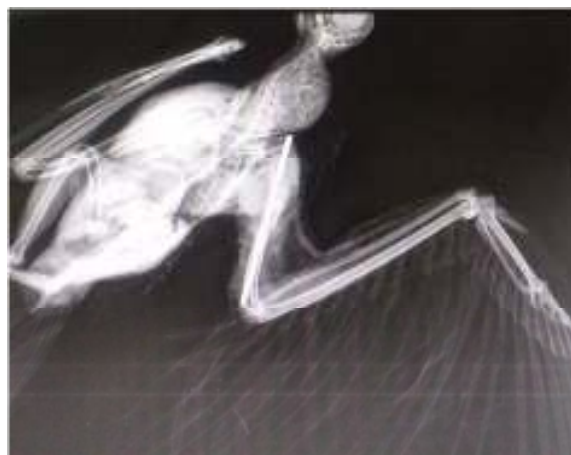

Figure 2: Radiograph after the surgical correction of the fracture

RESULTS

The bird has an uneventful recovery from the surgery. The bird was given inj. Ceftiofur sodium (Xyrofur® 0.5g) @ 0.91mg/kg BW s/c and inj. tribivet 0.2ml s/c for 7 days and advised Staphbhan ointment (Povidone iodine) bandaging on alternate days. The bird was advised cage rest for a month and review by the end of the month.

DISCUSSION

The traditional objectives of healing in avian orthopedics are the same as those in mammalian orthopaedics and it includes rigid fixation, good

alignment, good apposition, asepsis, and early return to function which forms the basic principle of fracture repair in birds. Also, maintaining the length of the bones is important in birds owing to balance of the animal and the special mechanics of flight (Redig and Roush, 1978). Attainment of these objectives is no easy mission in birds. In the present case IM pinning was attempted in order to achieve the classical objectives at the earliest.

Molting, a yearly occurring phenomenon in most birds, causes an increase in the susceptibility of the long bones to fracture. This functional "osteoporosis" is due to an enlargement of the Haversian systems. The reason of the present fractures remains unknown as the bird is wild. As the vascularity of the bones decrease the healing time increases. This problem is especially pronounced in humeral and femoral fractures. The callus in bird fractures forms primarily on the inside of the bone. This gives excellent stability and reduces healing time but also reduces the efficacy of intramedullary devices for fracture repair (Westfall and Egger, 1979). The biggest differential diagnoses in avian fractures are bone tumors, easily identified by their lack of pain (Arnall and Keymer, 1975). In this case, no sign of bone tumor was observed on detailed examination. The orthopedic procedure is often successful but the bird dies as a result of stress associated with the injury, anesthesia or surgery (Bushet. *al.*, 1975; Wingfield and de Young, 1972). The most serious of these is the risk of anesthesia. Before surgery is attempted it should be recalled that gas exchange occurs during exhalation (while the gas is passed from the air sacs into the lungs and trachea) and not on inspiration as in mammals; thus there is a lag time for resuscitation and anesthesia. The problem of maintaining body heat in birds over lengthy procedures is an often encountered problem. The commonly available screws and pins utilized for fracture fixation are usually too big and too heavy for all but the largest psitticines and raptors. Not the least of the surgical problems are the lack of adequate interest by veterinarians and appropriate reference materials. In this case surgical correction was performed in spite of all odds. Probably the most common complication in healing of avian fractures is sepsis (Amand, 1977). The small muscle mass and thin skin give rise to frequent compound fractures, especially that of the wings. Osteomyelitis, which is a common problem in mammals, is relatively rare in birds, presumably due to their increased body temperature. However, compound fractures involving the humerus and femur leave an open path into the air sacs and air sacculitis may be seen. Care was taken to avoid the occurrence of sepsis in the reported cases.

Internal fixation may be used for fracture management in both medium and large birds in much the same manner as mammals. The major problem involves the lack of appropriate sizes of pins, screws and plates. Most of these were developed for human or small animal use. Consequently, their size and weight are prohibitive, except for the larger raptors. Other problems associated with internal fixation include providing adequate exposure, minimal sepsis and articulation insult. In small birds K-wires or 18 to 26 gauge hypodermic needles may be used for intramedullary pinning (Mandrill, 1975). Care must be taken when installing these, as small bones tend to splinter very easily. Steinman pins may be used for retrograde pinning of the humerus but seem to be of more value in ulnar fractures when the radius is also fractured. Two distinct disadvantages of all intramedullary pins are the lack of dense bone in the metaphyseal region of the bones and the presence of very fine bony trabeculae throughout the length of the bone. These allow for pin migration and rotational instability around the pin at the fracture site. Another disadvantage involves the use of Steinman pins which are slightly tight in the marrow cavity. The thin cortices of the avian bone tend to fissure fracture quite readily. If this is the case, a slightly smaller pin should be used in conjunction with devices to prevent rotation. Cerclage wires can easily be applied to prevent the fissure fractures from extending. Finally, pins tend to extend into joints and result in stiffness, severely limiting the ability of the bird to perform. The K-wire in combination with cerclage wiring was selected for the grey heron with an intention to provide rigid apposition without rotation of the bones, along with space for respiration. The fixators were also selected based on the possible additional weight that the bird would have to bear.

ACKNOWLEDGEMENT

Authors are grateful to District Veterinary Centre, Thiruvananthapuram, Kerala for providing all the facilities and to the authorities of 27th Swadeshi Science Congress for giving an opportunity for this venture.

REFERENCES

- Amand W.B., 1977. General techniques in avian surgery, In Kirk, R. W. (ed.): Current Therapy VI. Philadelphia, W. B. Saunders Co., pp. 715-716.
- Arnall L. and Keymer I.F., 1975. Bird Diseases. London, Bailliere, Tindall, pp. 408-413.

- Bush M., Hughes L., Ensley P.K. and James A.E., 1976. Fracture repair in exotics using internal fixation. *JAAHA*, **12**:746-753.
- Helmer P. and Redig P.T., 2006. Surgical resolution of orthopedic disorders. In Harrison G.J., Lightfoot T.L. (eds.): *Clinical Avian Medicine, Volume II*. Palm Beach, FL: Spix Publishing, pp. 761-774.
- Mandrill D.N., 1975. Internal fixation in the treatment of fractures in birds. *Vict. Vet. Proc.*, p. 18.
- Redig P. and Roush J.C., 1978. Orthopedic and soft tissue surgery, In Fowler, M. E. (ed.): *Zoo and Wild Animal Medicine*. Philadelphia, W. B. Saunders Co., pp. 247-251.
- Redig P.T., 2008. The use of an external skeletal fixator intramedullary pin tie-in (ESF-IM Fixator) for treatment of long bone fractures in raptors. In Lumeij J.T., Remple J.D., Redig P.T., Llerz M., Cooper J.E. (eds): *Raptor Biomedicine III*. Lake Worth, FL: Zoological Education Network, pp. 239-253.
- Redig P.T., 2008. Anatomical and surgical considerations of the avian thoracic limb. *ProcAssoc Av Vet.*, pp.429-438.
- Westfall M.L. and Egger E.L., 1979. The Management of Long Bone Fractures in Birds. *Iowa State Uni. Veterinarian*, **41**(2).
- Wingfield W.E. and DeYoung D.W., 1972. Anesthetic and surgical management of eagles with orthopedic difficulties. *VMSAC*, **67**:991-993.