

THE STUDIES OF HELMINTH PARASITES FROM FAECAL SAMPLES OF FOUR SPECIES OF DEER IN DIFFERENT HABITATS OF THRISSUR DISTRICT

M. JAYA^{a1} AND M. AJA^b

^aDepartment of Zoology, Sree Kerala Varma College, Thrissur, India

^bDepartment of Zoology, Govt. College, Kariavattom, Trivandrum, India

ABSTRACT

Results of the present study indicated that helminth parasite infection were more common than protozoan infection in herbivore animals. The protozoans parasites were not recorded in the present study. The parasites recorded were the nematode *Strongyle* sp., cestode *Moniezia* sp. and trematode *Amphistome* sp. The *Strongyles* spp. were the most common parasites observed (46.75%) followed by *Moniezia* (42.86%) and *Amphistome* (10.39%). The samples were recorded negative for parasites collected from the faecal samples of field deer species.

KEYWORDS: Helminth Parasites, Faecal Samples, Deer Species

Zoos are an *ex-situ* form of conservation where animals are displayed in cages or enclosures for esthetic, educational or research, and conservation purposes. Parasites and infectious diseases have become a major concern in conservation of endangered species as they can lead to mortality, dramatic population declines, and even contribute to local extinction events (Smith *et al.*, 2009). In wild conditions, animals have some natural resistance against parasitic diseases and there is a state of equilibrium between the parasite and the host and it seldom lead to harmful infection unless stressed. The constant stress of captivity makes animals more susceptible to parasitic infection as the immune system of these captive animals becomes weak (Gracenea, 2002). To have a better understanding about the prevalence of the endoparasites affecting zoo animals, this study attempts to investigate the occurrence of helminth parasites of animals in Thrissur Zoo and under field conditions of selected localities. The present studies were carried out on four different species of deer (Spotted deer (*Axis axis*), Black buck (*Antelope cervicapra*), Sambar deer (*Cervus unicolor*) and Hog deer (*Axis porcinus*) captivated in Thrissur Zoo and compared it with field conditions.

The blackbuck also known as the Indian Antelope, is an antelope found in Pakistan, India and Nepal. The blackbuck is the sole extant member of the genus *Antelope*. Today, only small, scattered herds are seen, largely confined to protected areas. The blackbuck inhabits grassy plains and slightly forested areas. Hog deer appears to prefer dense forests; Hog deer has a native geographic range throughout India, including the Himalayan foothill zone and Southeast Asia, including Burma and Thailand. Spotted deer also known as Chital deer, is the native animal of the Indian subcontinent. The natural habitat of the Chital Deer comprises of Indian parkland habitats,

with open woodland in grassy areas. They prefer to live near rivers and other sources of water. Sambar deer (*Cervus unicolor*). The sub species of sambar in India and Sri Lanka are the largest of the genus with the largest antlers both in size and in body proportions. The sambar is distributed in much of southern Asia as far north as the south-facing slopes of the Himalayas, mainland Southeast Asia

MATERIALS AND METHODS

A total of 202 faecal samples from 4 species of captive and field animals including Spotted deer (*Axis axis*), Black buck (*Antelope cervicapra*), Sambar deer (*Cervus unicolor*) and Hog deer (*Axis porcinus*) were screened using classical parasitological techniques including sedimentation and floatation techniques. The Zoo officials of Thrissur granted permission for conducting experiments using the deer captivated in Zoo.

Study Site

The zoo compound includes a Zoological Garden, Botanical Garden, a natural history museum and an art museum that showcase the socio-cultural heritage of the region. The Thrissur Zoo is 2 kilometers (1.2 mi) from the Thrissur City center. All the four species, are housed in separate enclosures and are cleaned on a routine basis with necessary prophylaxis. These animals are fed with pellets, cotton seeds and grasses. The zoo is a closed type having no introduction of any outside animal at least for past 5 years.

Field Sites Include

a) Vazhakumpara, Thrissur: The sample site located at Chuvannamannu near (this particular land is located close to thrissur palakkad NH47 roadside tar road)

b) The south Wayanad division: is located 16 km east of Sulthan Bathery and north wayanad division 20 km from Mananthavady in the state of Kerala. Vayanad district is in the southern tip of the Deccan Plateau. Part of the Western Ghats is in the district.

The Collection of Parasites

A total of 202 faecal samples from four different species of deer were collected. Among 202 samples sampled in this study, 30 samples were collected from felid, the remaining (172) from captive conditions. Fresh samples were collected in plastic bottles from individual enclosures housing different species of deer's. The properly labeled plastic bottles containing the fecal samples were brought to the laboratory of the Department of Agriculture, Mannuthy, Thrissur for parasitological examination.

Collection and Preservation of Faecal Sample

Faecal samples must be properly collected in plastic or glass vials or bottles. Collection of samples directly from the rectum is always better. If this is not possible, fresh faeces may be collected from the field or floor. Ideally five grams of faeces should be collected. Since the eggs embryonate rapidly, the samples should be refrigerated unless examination is carried out within a day. If the samples are to be despatched to the laboratory for processing, they can be preserved by adding twice the volume of 10 percent formalin.

Sample Processing

The fecal samples were subjected to detailed routine parasitological analysis for the presence of parasitic eggs/oocysts by direct smear examination, standard sedimentation, and floatation technique. Helminthic infection are diagnosed by examining faeces, urine, blood and other secretions or excretions of the host for eggs, larvae or antigens of parasites. Of the different clinical materials, faecal sample examination is one of the tests done routinely for diagnosis of helminthosis. Faecal sample examination is commonly done for the diagnosis of gastro intestinal helminthic infections. The faecal sample is processed and examined for detecting helminthic ova. For the qualitative examination, the faecal samples are examined qualitatively for detection of helminthic infections. This can be by direct smear examination or by concentration techniques. The present study adopted Concentration method.

Concentration Method

In concentration techniques, the helminthic eggs present in the sample are concentrated either by sedimentation or flotation. So these methods are more sensitive than direct smear examination in terms of number of organisms demonstrated. Examination is easier since much of the debris in the faeces is removed by these techniques.

Sedimentation Method

In this method, about two grams of faeces is mixed with 15 ml of water or 10% formalin in a mortar with a pestle and then strained to remove the coarse particles. The filtrate is then transferred to a test tube and centrifuged at 3000 rpm for 2 min. The helminthic eggs will settle to the bottom of the test tube. The supernatant is then poured off and the sediment is examined under the microscope. Sedimentation is suitable for detecting most of the helminthic ova in faeces. However certain ova like schistosoma ova hatch quickly when it comes in contact with water. So such samples should be processed in 10% sodium or potassium hydroxide solution instead of water. Schistosoma eggs are mainly present in the mucus or blood passed out along with dung and this portion should be processed and examined. The alkali is mucolytic and is suitable for processing mucoid portions of the dung.

RESULTS AND DISCUSSION

This study revealed the presence of helminth parasites in four selected species of Deer captivated in Thrissur Zoo. However protozoan parasites are not recorded from the present study. Out of the total 202 fecal samples screened, 77(38.12%) samples were positive for gastrointestinal parasitic infection as given in T-1 to T- 5. The fecal samples collected from the field also recorded none of the parasite (T-6). The parasites identified include *Strongyle* (nematode or round worm), *Moniezia* (cestode or tape worm) and *Amphistome* (Trematodes or flukes). The summary of the results obtained are represented (T-7) and the percentage of each parasite recovered from the sample are also noted (T- 8 and Fig.3). The eggs/oocysts of three different types of parasites were observed in the study including *Strongyle* (46.75 %), *Moniezia* (42.86 %) and *Amphistome* (10.39 %).

Parasitism is a huge problem of livestock which lowers the productivity. When the parasitized animal is brought from wild to captivity, despite quarantine measures, the new condition of zoos is generally unfavorable for the animal but favorable to the parasites.

Occurrence of parasites in animals housed in zoo might vary according to the type of husbandry practices, disease prophylaxis and treatment administered. Various workers have recorded incidence of different parasites in captive wild animals (Chakraborty et al 1994). The eggs/oocysts of three different types of parasites were observed in the study including Strongyle (46.75%), Moniezia (42.86%), Amphistome (10.39%). However, protozoans parasites were not recorded in the present study. The gastrointestinal parasites species identified in this study have previously been recorded in captive animals in various zoos and zoological garden by other authors. Fagiolini *et al.*, 2010 reported helminth infection was more common than protozoan infection with nematode eggs observed in 19 (90%) affected animals while protozoans were observed in only 8 (38%) animals out of the total positive animals. The intensive husbandry of wild animals in zoos and zoological parks may be one of the reasons for the higher infection as high animal density in enclosures and their proximity to other species of animals provides opportunity for transmission of parasites. Moreover, it has been observed that confinement of wild animals in zoo makes them more prone to different parasitic infections despite proper attention to feeding, water, and maintenance of hygiene in captivity. The nematodes and some coccidian parasites have a direct life cycle, i.e., they do not involve any intermediate host and are transmitted by feco-oral route through contaminated feed, water, and soil and have the potential to accumulate in a captive environment. This could be due to the fact that these parasites (mainly trematodes and some cestodes) require an intermediate host for their transmission and are less likely to accumulate in the captive environment.

The environmental contamination could be through contaminated water or fodder, and even zoo workers have also been reported to play a role in transmission by acting as vectors and transmitting parasites through their shoes, clothes, hands, food, or with working tool. Usually, captive animals do not show alarming signs of parasitism if regular deworming practices carried out in the zoo (Parasani *et al.*, 2001). This is supported by the results of present study. Because of the effective deworming practices most of the time animals are free from worms.

Table 1: The Analysis of endoparasites in faecal samples of deer from captive locality dated 6/11/2016

Species selected	Prevalence of Endoparasites
1. Black buck (<i>A. cervicapra</i>)	Negative
2. Hog deer(<i>A. porcinus</i>)	Negative
3. Sambar deer(<i>C. unicolor</i>)	Negative
4. Spotted deer(<i>A. axis</i>)	Negative

Table 2: The Analysis of endoparasites in faecal samples of deer from captive locality dated 19/12/2016

Species selected	Prevalence of Endoparasites
1. Black buck (<i>A. cervicapra</i>)	<i>Strongyle</i>
2. Hog deer(<i>A. porcinus</i>)	<i>Moniezia</i>
3. Sambar deer(<i>C. unicolor</i>)	<i>Strongyle</i>
4. Spotted deer(<i>A. axis</i>)	<i>Strongyle</i>

Table 3: The Analysis of endoparasites in faecal samples of deer from captive locality dated 21/1/2017

Species selected	Prevalence of Endoparasites
1. Black buck (<i>A. cervicapra</i>)	<i>Moniezia</i>
2. Hog deer(<i>A. porcinus</i>)	<i>Moniezia</i>
3. Sambar deer(<i>C. unicolor</i>)	<i>Amphistome</i>
4. Spotted deer(<i>A. axis</i>)	negative

Table 4: The Analysis of endoparasites in faecal samples of deer from captive locality dated 18 /2/2017

Species selected	Prevalence of Endoparasites
1. Black buck (<i>A. cervicapra</i>)	Strongyle
2. Hog deer(<i>A. porcinus</i>)	Negative
3. Sambar deer(<i>C. unicolor</i>)	Negative
4. Spotted deer(<i>A. axis</i>)	Negative

Table 5: The Analysis of endoparasites in faecal samples of deer from captive locality dated 22/3/2017

Species selected	Prevalence of Endoparasites
1. Black buck (<i>A. cervicapra</i>)	Negative
2. Hog deer(<i>A. porcinus</i>)	Negative
3. Sambar deer(<i>C. unicolor</i>)	Negative
4. Spotted deer(<i>A. axis</i>)	Negative

Table 6: The Analysis of endoparasites in faecal samples of deer from field

Date	Locality	Animals	Endoparasites
1. 12/12/2016	Vazhukkumpara	Spotted deer(<i>A.axis</i>)	Negative
2. 18/1/2017	Pookode(Wayanad)	Sambar deer(<i>C.unicolor</i>)	Negative

Table 7: Summary of the parasites obtained

Sl.no	Animals	Locality	Endoparasite identified	Number of fecal sample collected
1	Black buck (<i>A. cervicapra</i>)	Zoo	<i>Strongyle</i>	18
			<i>Moniezia</i>	10
			Negative	16
2	Hog deer(<i>A. porcinus</i>)		<i>Moniezia</i>	23
			Negative	28
3	Sambar deer(<i>C. unicolor</i>)		<i>Amphistome</i>	8
			<i>Strongyle</i>	6
			Negative	17
4	Spotted deer(<i>A. axis</i>)		<i>Strongyle</i>	12
			Negative	34
5	Sambar deer(<i>C. unicolor</i>)	field	Negative	13
6	Spotted deer(<i>A. axis</i>)		Negative	17

Table 8: The Percentage of each parasite recovered from the sample

Name of parasite	Percentage of parasite identified in faecal sample
<i>Strongyle</i>	46.75 %
<i>Moniezia</i>	42.86 %
<i>Amphistome</i>	10.39 %

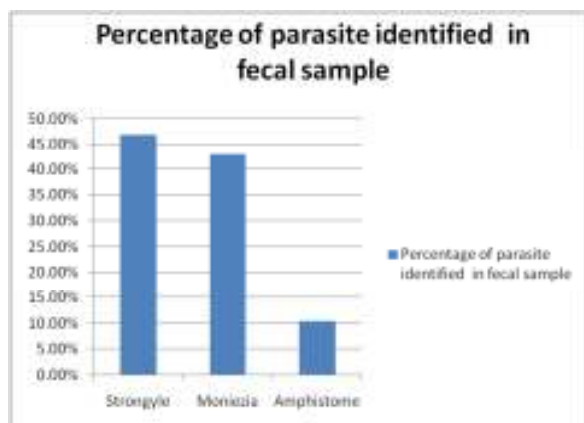


Figure 1: The different proportions of parasites in fecal sample collected from zoo

SUMMARY AND CONCLUSION

The fecal samples of 202 captive and field animals at different locations were analysed to study parasitism. Results indicated that helminths infection were more common than protozoan infection in herbivore animals. The protozoans parasites were not recorded in the present study. The parasites recorded are the nematode *Strongyle* sp., cestode *Moniezia* sp. and trematode *Amphistome* sp. *Strongyles* spp. were the most common parasites observed (46.75%) followed by *Moniezia* (42.86%) and *Amphistome* (10.39%). The samples were recorded negative for parasites collected from the faecal samples of field deer species.

ACKNOWLEDGEMENT

We also express our sincere thanks to authorities of 27th swadeshi science congress for giving the opportunities to publish our research work. We express our great gratitude to Dr. Binoy. C. Babu (Bvsc, AH) State Museum and Zoo, chembukavu, Thrissur for permitting us to collaborate with Zoo and use facilities in addition to giving us the timely advice.

We are extremely thankful to Dr. Lucy (Ph.D, Head of Parasitology Department, College of veterinary and Animal Science, Mannuthy, Thrissur) for their invaluable help, guidance and suggestions without which

this work could not have been completed. We also extend our gratitude to the entire team of College of veterinary and Animal Science for providing their lab that enabled this project work.

We are very thankful to the guidance of zoo keepers in State Museum and Zoo and also lab assistants in College of veterinary and animal science.

REFERENCES

- Parasani H.R., Momin R.R., Maradin M.G. and Veer S., 2001. A survey of gastrointestinal parasites of captive animals at Rajkot municipal corporation zoo, Rajkot, Gujarat. *Zoo's Print Journal*, **16**(10):604-606.
- Smith K.F., Acevedo-Whitehouse K. and Pedersen A.B., 2009. The role of infectious diseases in biological conservation. *Anim. Conserv.*, **12**: 1-12.
- Gracenea M., Gomez M.S., Torres J., Carne E. and Fernandez-Moran J., 2002. Transmission dynamics of *Cryptosporidium* in primates and herbivores at the Barcelona Zoo: A long-term study. *Vet. Parasitol.* **104**: 19-26.
- Parasani H.R., Momin R.R., Maradin M.G. and Veer S., 2001. A survey of gastrointestinal parasites of captive animals at Rajkot Municipal Corporation Zoo, Rajkot, Gujarat. *Zoo's Print Journal*, **16**(10): 604-606.
- Fagiolini M., Riccardo P.L., Piero L., Paolo C., Riccardo M., Claudia C., Riccardo F. and Stefania P., 2010. Gastrointestinal parasites in mammals of two Italian zoological gardens. *Journal of Zoo and Wildlife Medicine*, **41**(4): 662-670.
- Chakraborty A., 1991. Incidence and etiopathology on the mortality of captive wild herbivores in Assam. Ph.D. Thesis. Assam Agricultural University. Assam.