

RESULTS OF INTERTROCHANTERIC FRACTURES FIXED WITH DYNAMIC HIP SCREW FIXATION

AMIT BATRA^a, ANKUR DHIMAN^{b1}, MOHIT KHANNA^c, ANIL GULIA^d, SHUBHAM JOSHI^e,
ROOP SINGH^f AND ADITYA JAIN^g

^{abcdefg}Department of Orthopaedics, Pt. B. D. Sharma, PGIMS, Rohtak, Haryana, India

ABSTRACT

Numerous internal fixation devices have been used to stabilize intertrochanteric fractures. We have analyzed the results of the intertrochanteric fractures treated with dynamic hip screw fixation. 33 patients (13 males, 20 females) were included. Range of age was 50-90 years, right side involved in 21 cases whereas left side in 12 cases and classified according to Boyd and griffin classification system. All patients were investigated and treated with dynamic hip screw fixations. Patients were followed up at regular intervals. Thirty-three patients of intertrochanteric fractures were included in the study with an average age group of 70 years. The union occurred in 31 fractures and 2 non-unions with screw cut through anteriorly. Seventeen patients had some amount of shortening. Six patients had short limb gait, 5 patients were using a cane on ipsilateral side for assisted walking. The results were analyzed using the Harris Hip Scoring System.

KEYWORDS : Intertrochanteric Fracture, Dynamic Hip Screw, Extramedullary, Union

Intertrochanteric fracture is one of the most common fractures of the hip especially in the elderly people, usually due to trivial trauma like simple falls. The incidence of the senile hip fractures has been rising due to increase in the aging population in most parts of world. (Cummings et al., 1990.) Such fractures are increasingly seen with increasing frequency as the life expectancy of our population is steadily increasing. The primary goal of the treatment of such fractures is to return the patients to their pre - fracture activity levels. Rapid mobilization and rehabilitation of these elderly patients reduces the morbidity and mortality rate in geriatric patients.

Before the introduction of suitable fixation devices, treatment of intertrochanteric fractures was non-operative, consisting of prolonged bed rest in traction and abduction until fracture healing occurred. It was followed by a lengthy program of ambulation training and rehabilitation. In elderly patients, this approach was obviously associated with high complication rates and associated problems like decubitus ulcers, urinary tract infections, joint contractures, pneumonia and thromboembolic complications that resulted in high mortality rate. This type of treatment was frequently accompanied by varus deformity and shortening because of the inability of traction to effectively counteracts the deforming muscular forces. The treatment of choice in these fractures is now closed/ open reduction and internal fixation.

Numerous internal fixation devices have been used to stabilize intertrochanteric fractures, and they can be divided into 2 categories: extramedullary fixation devices and intramedullary fixation devices. The sliding devices have gained universal popularity as the fixation device for most if not all intertrochanteric fractures. Various modifications of Dynamic Hip Screw are available in market such as Medoff's plate, trochanteric stabilizing plate, augmentation with Tricalcium phosphate cement and Hydroxyapatite (H.A) coated screw (Medoff et al., 1990) Cheug et al., 1989) Each modification has its own advantages and disadvantages. DHS offers the advantages of being a simple, predictable surgical technique which has given consistently successful results in the past. It has the advantage of controlled impaction and progressive stabilization, Because of the blunt tip, the implant does not penetrate into the acetabulum and because of good stability, it allows early mobilization and allows for early weight bearing. Despite these theoretical and biomechanical advantages, sliding hip screw constructs have limitations. Excessive collapse can result in failure of the procedure. Cutout of implant may occur in severe osteoporotic bones and after improper implant placement. In some conditions like reverse oblique fracture, intertrochanteric fractures with subtrochanteric extension, 3 part or 4 part unstable fractures intramedullary implants are thought to be more helpful than extramedullary implants. Recently, there is a tendency of increased use of intramedullary nails

¹Corresponding author

(Schumplik et al., and Jansten P.M., 1995, Mathew et al., 2004). Intramedullary Sliding Hip Screw devices (Gamma nail) have recently been developed for stabilization of pertrochanteric fractures. These devices combine the properties of a sliding hip screw with a locked intramedullary nail. Proximal femoral nail (PFN) is recent advance in intramedullary implants in pertrochanteric fractures. It has advantage of more stable fixation and prevention of rotational deformity but it is a demanding procedure. Thigh pain is another problem associated with intramedullary procedures and it carries risk for femoral shaft fracture at the nail tip and the insertion sites of the distal locking screws (Atrengart et al., 2002 and Docquet, 2002). Although the results of PFN and DHS in treatment of intertrochanteric fractures have been reported, the results and conclusions are not consistent (Zhao et al., 2009). In present study, we have analyzed the results of the intertrochanteric fractures treated with dynamic hip screw fixation.

MATERIALS AND METHODS

Thirty five patients with intertrochanteric fractures treated with DHS fixation were selected for the study, of which 2 patients of over 70 years expired after the 6

months post operatively. Hence the total number of patients included in the study was 33 patients. (Table 1) The follow up period ranged from 7 months to 2 1/2 years. Compound fractures, pathological fractures and fractures in children were not included in the study.

All of the patients were put on skeletal traction on admission and were investigated for anaesthetic fitness. Average time interval between admission and surgery was 8.5 days (range 7-20 days). Patients were positioned supine on a fracture table or conventional table. Skin incision was made from about 1 inch below the tip of the greater trochanter extending down the shaft of the femur for about 8 cm. Subcutaneous fat and underlying deep fascia was incised and fibers of vastus lateralis were split along its line of fibers and retracted. The guide wire was inserted from the level of tip of the lesser trochanter towards the apex of the femoral head. A careful and conscious effort was made to place the tip of the wire in center of the head in anteroposterior and lateral views or in the posterior and inferior quadrant of the head. Central or posterior placement of wire was confirmed on the lateral view. Another parallel guide wire was inserted to provide temporary stability to the fracture. Once the guide wire was inserted, the requisite lag screw length was determined, the guide wire was advanced

Table 1 : Data of Patients Included in Study

Categories	Variables	Number of Patients	Total
AGE (yrs)	<60	2	33
	60-70	16	
	70-80	12	
	80-90	3	
Sex	Male	13	33
	Female	20	
Mode of injury	RTA	3	33
	Trivial violence	30	
Side of injury	Right	21	33
	Left	12	
Boyd and griffin classification	Type 1	3	33
	Type 2	15	
	Type 3	7	
	Type 4	8	
Associated injury	Colle's fracture	2	33
	No associated injuries	31	
Associated medical problems	Diabetes mellitus	16	33
	Hypertension	12	
	Ischemic heart disease	4	
	None	1	

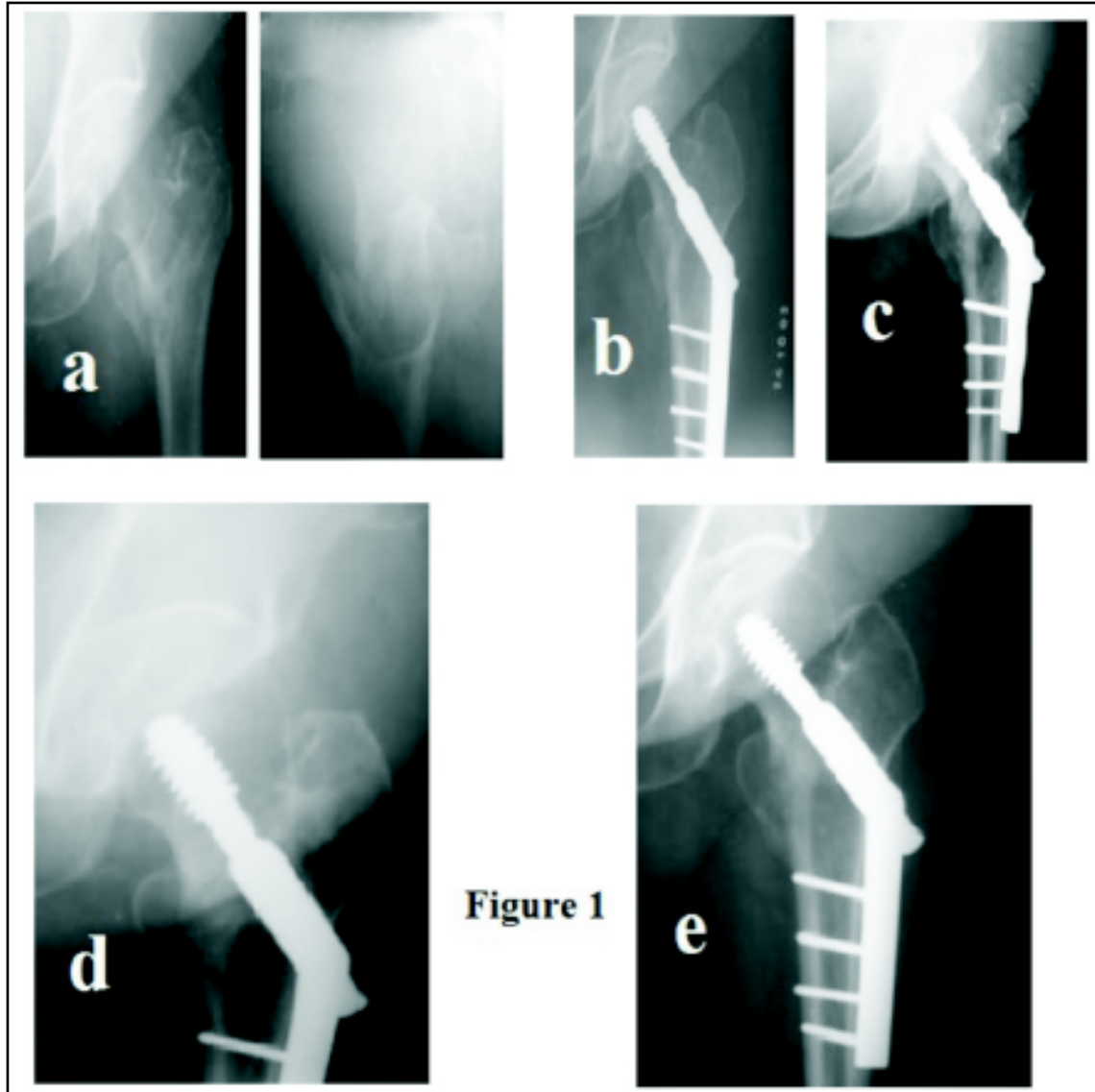


Figure 1 : A : Shows Case of Intertrochantric Fracture

B : Immediate Post-operative X-ray of Intertrochantric Fracture Managed With Dynamic Hip Screw

C : X-ray At 3 Month Follow-up

D : X-ray At 6 Month Follow-up Showing Bridging Callus Formation

E : X-ray At 1 Year Follow-up

to additional 5 mm into the subchondral bone, reamed with triple reamer and then the tapping was done. The lag screw was inserted into the reamed hole up to the subchondral bone and verified with image intensifier in both antero-posterior and lateral views. The insertion wrench, lag screw retaining rod and guide wires were removed. The plate clamp was used to secure the plate to the shaft and then traction released to allow impaction. Finally the plate was

attached to the shaft of femur with 4.5 mm cortical screws. Compression screw was inserted in end to produce compression at fracture site. Patients were followed up at 1 month, 3 months and 6 months for assessment of union (radiologically and clinically) and then followed up annually. Callus present on all cortexes in both antero-posterior and lateral view with disappearance of fracture line were considered as the healed fracture and Loss of

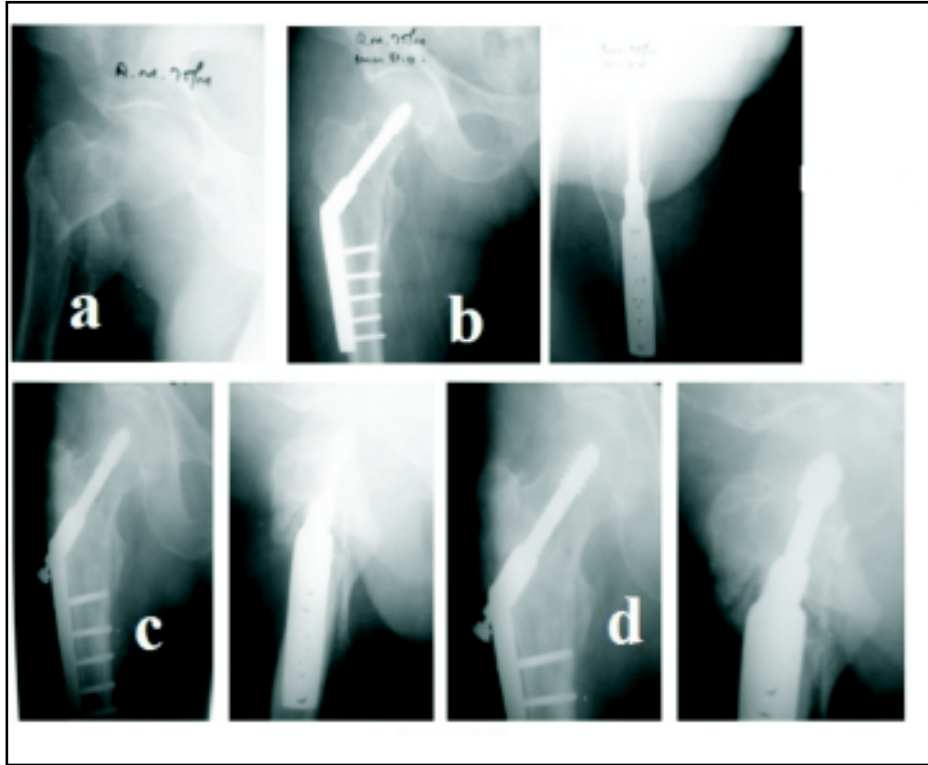


Figure 2 :

- A : Shows Another Case of Intertrochantric Fracture**
- B : A-p And Lateral Views Of Immediate Post-operative X-rays**
- C : A-p And Lateral Views Of X-rays At 3 Month Follow-up**
- D : A-p And Lateral Views Ofx-rays At 6 Month Follow-up**

fixation, implant cut through, symptomatic joint penetration, non functional malunion or nonunion were considered as treatment failure.

RESULTS

Thirty-three patients of intertrochanteric fractures were included in the study with an average age group of 70 years. The average follow-up period was nine months and average duration of stay in the hospital of 13 days. The union occurred in 31 fractures and 2 non-unions with screw cut through anteriorly (Table 2). Seventeen patients had some amount of shortening with 11 patients having a shortening of 0-1 cm, 4 patients with 1-2 cm of shortening and 2 patients with >2 cm shortening. Six patients had short limb gait 5 patients were using a cane on ipsilateral side for assisted walking. Two patients with non-union developed coxa-vara with screw cut through and had to be reoperated with 120 degree double angled osteotomy blade plate with

valgus osteotomy. The results were analyzed using the Harris Hip Scoring System and the patients were categorized according to the scores they attained as follows: excellent: 100 90, good: 89 80, fair: 79 70, poor: < 70. (Harris hip score; Harris WH; JBJS 1969).

Table 2 : Results of Dynamic Hip Screw Fixation in Intertrochantric Fractures

Categories	Variables	Number of Patients
Rate of union	Union	31
	Non-union	2
Shortening	0-1 cm	11
	1-2 cm	4
	>2 cm	2
Harris hip scoring system	Excellent	18 (54.54%)
	Good	8 (24.24%)
	Fair	5 (15.15%)
	Poor	2 (6.06%)

DISCUSSION

Figure 1 & 2 are showed in text mention. The dynamic hip screw with a side plate fixation remains the most common method of treating the intertrochanteric hip fractures. Conventional surgical technique of fracture reduction and fixation with DHS barrel plate and the lag screw has stood the test of time. Recently, the main goal of treatment is decrease analgesic requirement, cost and operating room time, early mobilization and decreased hospital stay. Although with the use of new implants these goals can be achieved easily but these implants are generally costly and the procedure is technically demanding. Cephalomedullary nails have been designed to realize these aims; however a meta-analysis of the published trials shows that some of these devices had a significantly increased risk of fracture of the femoral shaft and an increased re-operative rate (Hardy et al., 1998).

The varus collapse of the head and neck caused by lag screw cut-out or lateral protrusion is one of common post-operative complications that lead to surgical failure of treatment of intertrochanteric fractures. Lag screw cut-through is thought to be caused either by improper lag screw placement in the anterior and/or superior quadrant of the head or by not placing the screw upto to the subchondral region of the head. (Baungaertner and Solberg, 1997) Chatterjee et al reported coxa vara in 3 cases due to cutting out of screw through head & neck of femur and also proximal migration of DHS with avascular changes of the femoral head in one case (Chaterjee et al., 1991). Heyse-Moore et al. (1983), retrospectively compared the results of 107 intertrochanteric fractures stabilized with a sliding hip screw to 103 fractures treated with a Jewett nail and concluded that the patients treated with sliding hip screw had shorter hospitalization stays and a lower incidence of fixation failure (Heyse- moorel; 1983). Bannister et al, in a prospective randomized study of 155 intertrochanteric fractures stabilized using sliding hip screw and Jewett nail, found that fractures that fractures stabilized with sliding hip screw had a significantly lower risk of mechanical failure and a lower incidence of revision surgery (Barrister G; 1990). Jacobs et al., (1976) reported on a series of 173 intertrochanteric fractures treated with internal fixation, 72

with a Jewett nail and 101 with a Sliding Hip Screw (Jacobs, 1976). Treatment failure occurred in 25% of fractures stabilized with a Jewett nail and in 6% of fractures stabilized using a Sliding Hip Screw. Leung et al, reported on a prospective series of 186 peritrochanteric fractures stabilized with either a Gamma nail or Sliding Hip Screw. Gamma nails were inserted in a significantly shorter operative time using a smaller incision and were associated with a smaller estimated blood loss. There was, however, no significant difference between the two groups with regard to post-operative mobility or hip function at follow-up. A higher number of intraoperative complications occurred in fractures stabilized with a Gamma nail (Leung K. S., 1992). Baumgartner et. al. (1998), reported on a series of 131 patients (135 fractures) who sustained an intertrochanteric fracture and were randomly assigned to treatment with either a Sliding hip Screw or an Intramedullary Hip Screw (IMHS) device. In patients with unstable intertrochanteric fractures, the intramedullary device was associated with significantly less surgical time and blood loss. Intraoperative complications occurred exclusively in the Intramedullary Hip Screw group. At latest follow-up, there was no difference in the percentage of functional recovery between the two fixation groups (Baungaertner, 1998). Hardy et al performed a prospective, randomized study comparing use of a Sliding Hip Screw to use of an Intramedullary Hip Screw (IMHS) for stabilization of 100 intertrochanteric fractures in patients age 60 years or older. The in-hospital and 6-month mortality rates were similar between the two treatment groups. The intramedullary hip screw was associated with significantly less screw sliding and limb shortening than the Sliding Hip Screw, particularly when used to stabilize unstable fracture patterns. Based on the results of this study, it was concluded that routine use of the Intramedullary Hip Screw could not be recommended for stabilization of intertrochanteric hip fractures (Hardy; 1998). Our results are comparable to the other studies and shows that DHS gives good biomechanical stability, is not much technically demanding, can be easily done on conventional table also and is quite cost effective as compared to the other commonly available implants.

CONCLUSION

We conclude that dynamic hip screw is a reliable, versatile and cost effective device for the treatment of most intertrochanteric fractures.

REFERENCES

- Atrengart L., Tornkvist H., Fornander P., Thorngren K. G., Passanen L. and Lindgren V. A., 2002. Randomized study of the compression hip screws and gamma nail in 426 fractures Clin. Orthop;401: 209-211.
- Barrister G., 1990. The fixation and prognosis of throchanteric fractures ; A Randomized prospective control trial; Clin orthop; 254, 242-46
- Baumgaertner M. R. and Solberg B. D., 1997. Awareness of tip-apex distance reduces failure of fixation of trochanteric fractures of the hip. J Bone Joint Surg Br; **79**: 969-71
- Baungaertner M., 1998. Intramedullary vs Extramedullary fixation for treatment of intertrochantric hip fracture; Clin orthop, **348** : 87-94.
- Chaterjee N. D., Bhattacharya G. and Bhattacharya T., July 1991. Dynamic hip screw and sliding plate for trochanteric fractures of femur; Review; **34**; No:3.
- Cheug C. L., Chow S. P., Leons T. C. V., 1989. Long term results and complications of cement augmentation in the treatment of unstable trochanteric fractures. Injury 134.
- Docquet P. L., Manche E., Actrique J. C. and Genletb. B., 2002. Complications associated with gamma nailing; A review of 439 cases; Acta Orthop Belg; **68**(3): 251-7.
- Hardy Dominique C. R., Descamps F. Y. and Kraths P., 1998. Use of an intramedullary hip screw compared with a compression with a plate for intertrochanteric femoral fractures. A prospective randomized study of 100 patients. J Bone and Joint Surgery (A); **80**:618-630.
- Hardy, 1998. Use of an intramedullary hip screw compared with a compression hip screw with a plate for intertrochanteric femoral fractures JBJS, **80-A**; 618-30.
- Harris hip score; Harris WH; JBJS 1969; **51**:1.
- Heyse- moorel, 1983. Treatment of intertrochanteric fractures of femur JBJS; 65-B; 262-267.
- Jacobs, 1976. Treatment of intertrochanteric hip fractures with a compression hip screw and a nail plate; J Trauma;**16** : 599-603.
- Leung K. S., 1992. Gamma nail and dynamic hip screws for petrochanteric fractures; A Randomised prospective study in elderly patients JBJS; 74-B; 345-351.
- Mathew DiPaolo B. A., S Robert Rozbruch and Helfet D. C., 2004. Minimal incision technique using a two plate for fixation of stable intertrochanteric hip fractures, J Orthopaedics: 126-132.
- Medoff R. J., Maes K., Mitsunaga M. and Chappuis J. L., 1990. Axial compression screw: anew implant for the fixation of the high subtrochanteric and unstable intertrochanteric fractures of the hip. Poster exhibit at the 53rd Annual Meeting of the American Academy of Orthopaedic Surgeons, New Orleans.
- S. R. Cummings, S. M. Rubin, and D. Black., 1990. "The future of hip fractures in the United States. Numbers, costs, and potential effects of postmenopausal estrogen," Clinical Orthopaedics and Related Research, no. **252** : 163-166.
- Schumplik W. and Jansten P.M., 1995. A new principle in the operative treatment of trochnanteric fractures of the femur; JBJS; **37**-4, 693-69
- Zhao C, Liu D-y, Guo J-j, 2009. Comparison of proximal femoral nail and dynamic hip screw for treating intertrochanteric fractures. China J Orthop & Trauma; 7: 535-37.